



ISAKOS PreCourse – Shanghai 2017

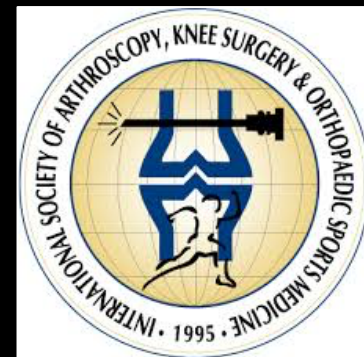

HTO vs UKA vs TKA

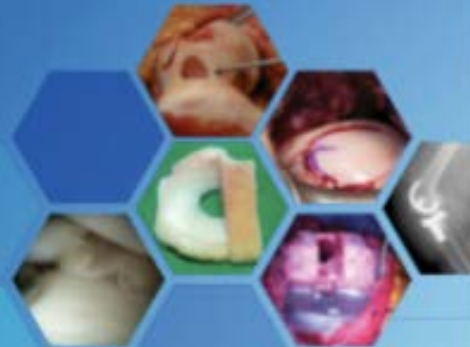Sébastien LUSTIG MD, PhD, Prof *

C Batailler, E Servien, P Neyret.

**Albert Trillat Center- Lyon, France*



David Parker
Editor



Management of Knee Osteoarthritis in the Younger, Active Patient

An Evidence-Based Practical Guide for Clinicians



 Springer

Periarticular Knee Osteotomy

6

Fernando Corbi, Rosa Ballis, Nicolas Gaggero,
and Sebastien Lustig

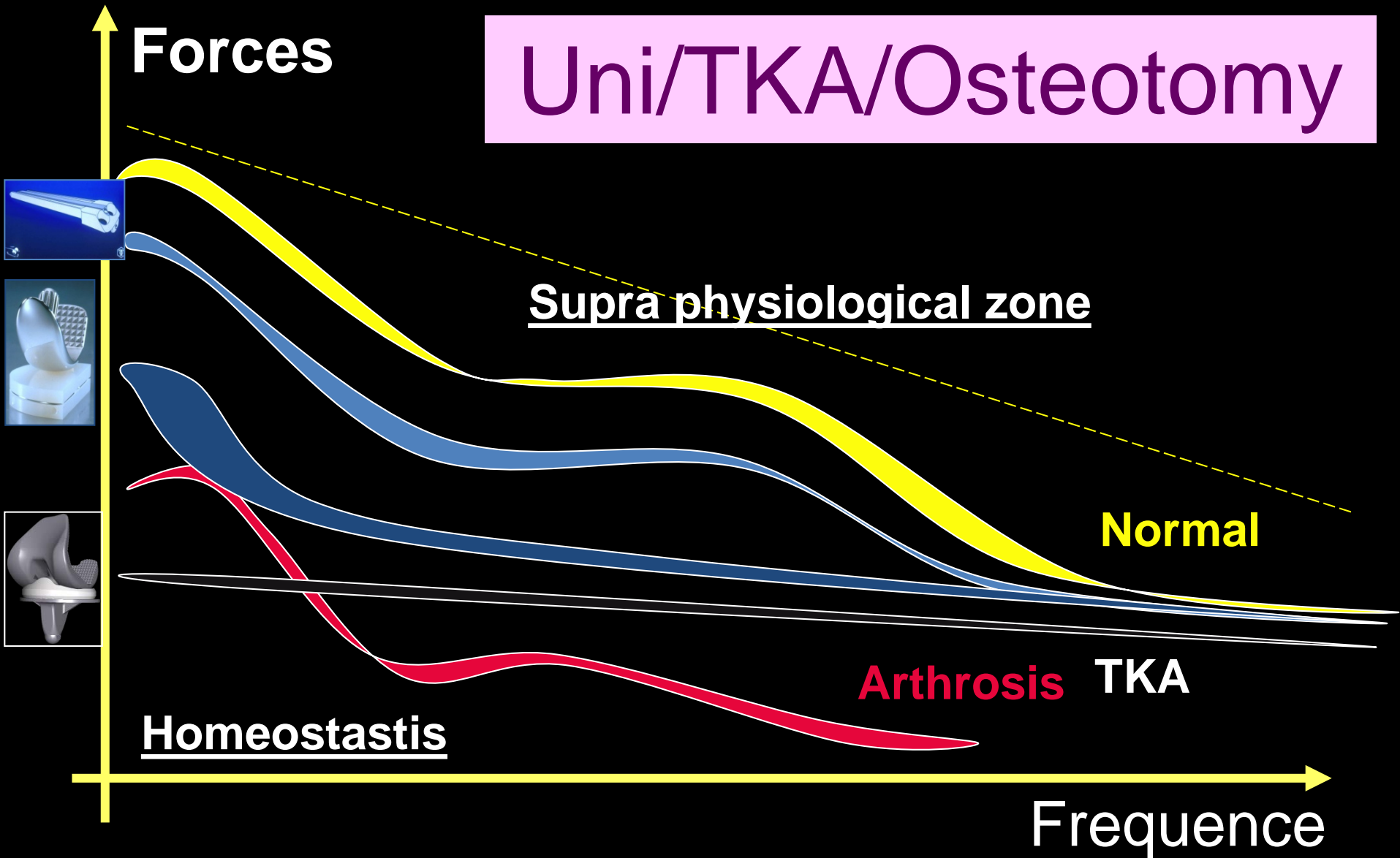
HOW DO WE MAKE THE RIGHT DECISION ?

- Correct assessment of the pathology
 - Patient related factors,
 - Anatomical factors ,
 - Ligamentous status .
- Understand patient expectations .
- Good knowledge of therapeutic options (and limits) .



Functional envelope (Dye, 1996)

Uni/TKA/Osteotomy



No True Algorithm


Anatomical criteria

- Stage of OA
- Analysis of the deformity and its reducibility
- Ligament status
- Range of motion

Clinical criteria

- Age and expectation
- Activity
- Weight
- General medical status (cardiovascular diabetes,plavix...)
- I Sepsis history

Osteotomy



Total
Knee arthroplasty

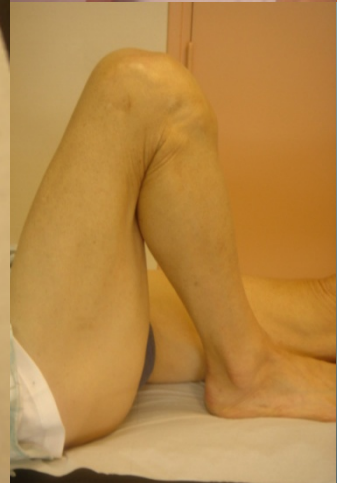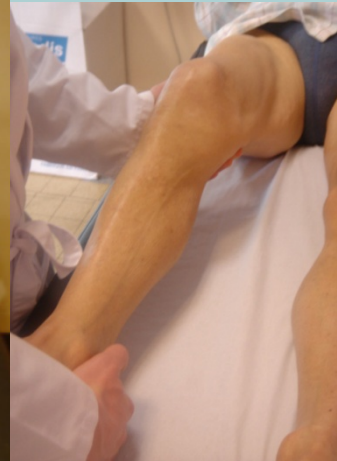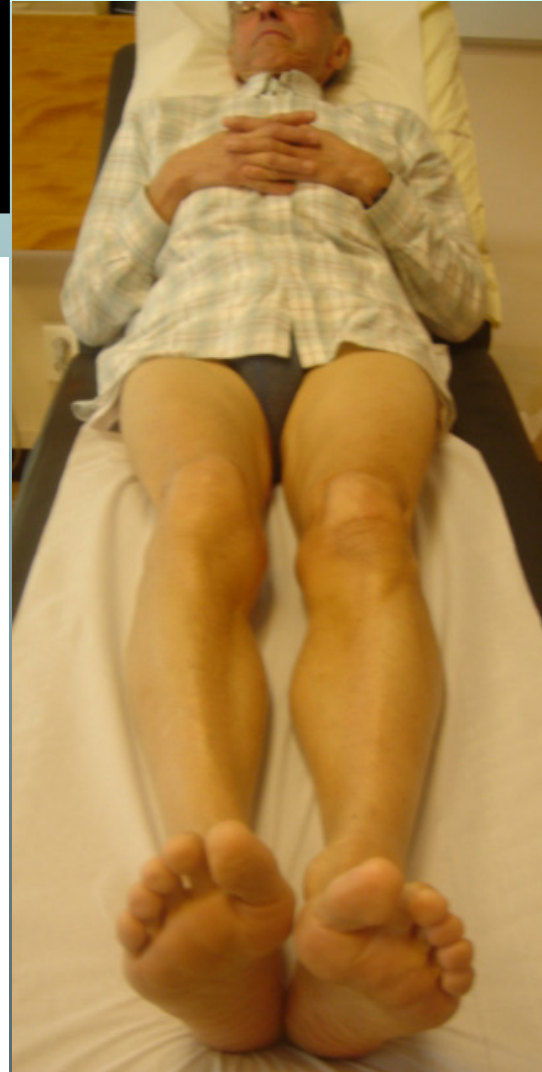Unicompartmental
knee arthroplasty

UKA

Ideal Candidate : Uni

Clinical Exam

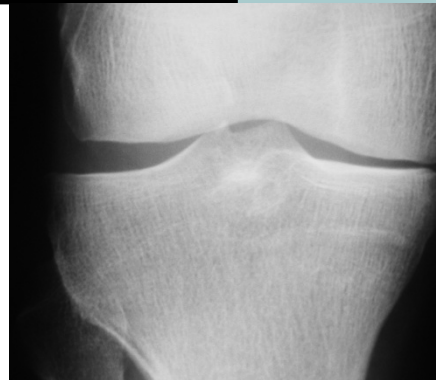- Pain at the joint line
- ROM almost normal
- No inflammatory history
- Normal ligament testing
- Reducibility of deformity
- Over 65 years old
- No obesity



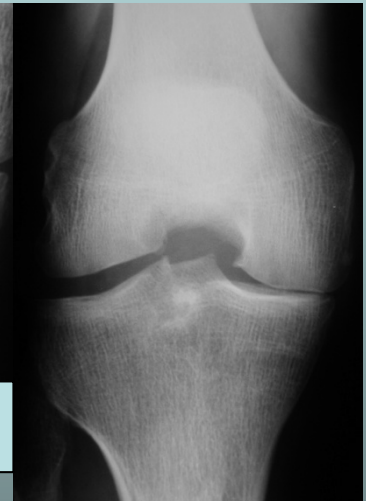
The Ideal Candidate

Radiological check-up

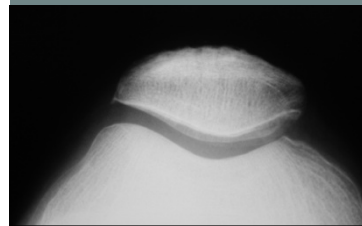
- Partial or **Complete Femoro-tibial narrowing**
- Uninvolved contralateral and patello-femoral compartment



A-P. monopodal



Schuss

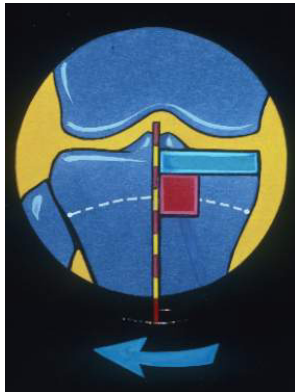


Axial view

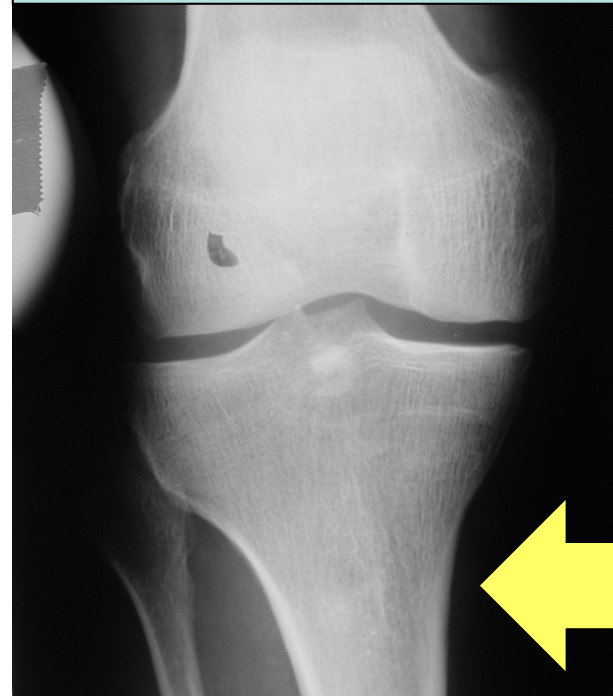
The Ideal Candidate

Radiological check-up

- Good reducibility
- Complete but...
- No Overcorrection



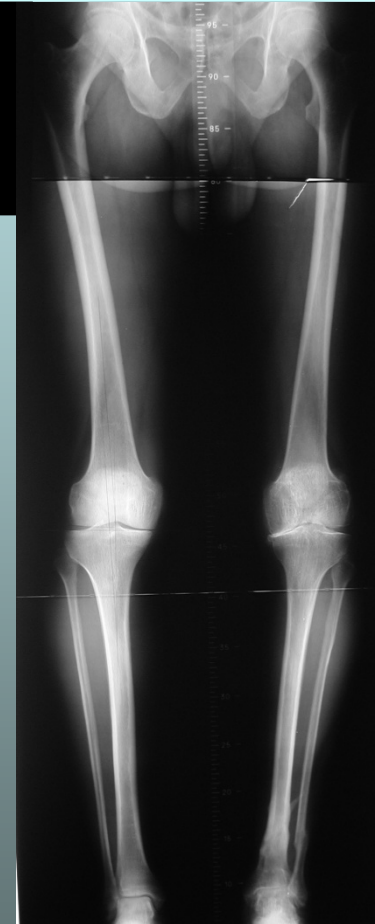
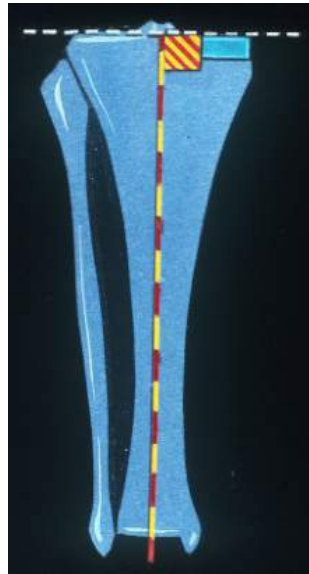
Stress X-Rays



The Ideal Candidate

Radiological check-up

- Extra-articular deformity
< 5 degrees



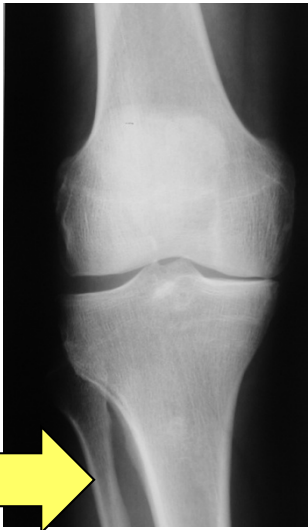Long leg film
HKA film

The Ideal Candidate

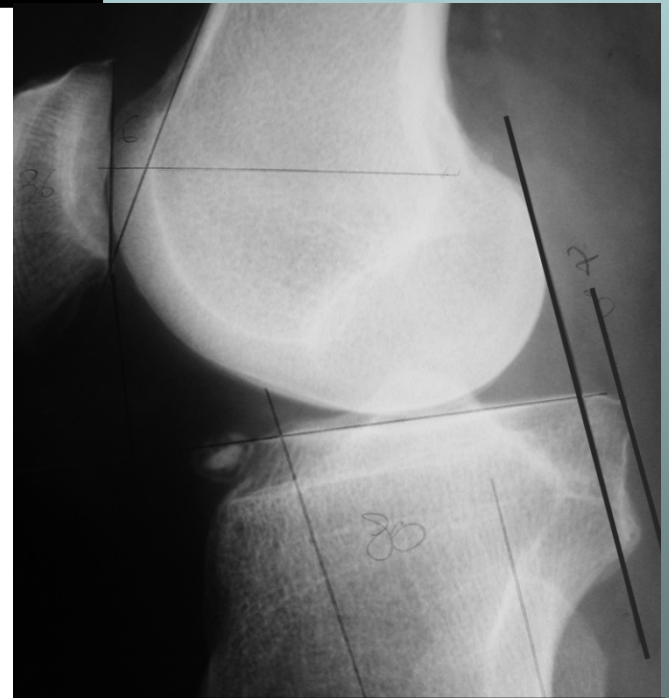
Radiological check-up

- No Laxity in the

- Convexity.....



- A-P. plane



Lateral monopodal
X-Rays

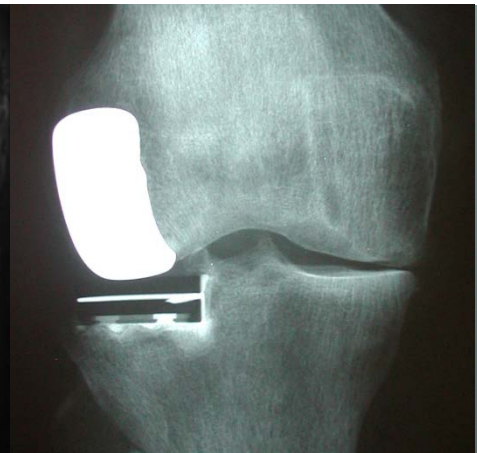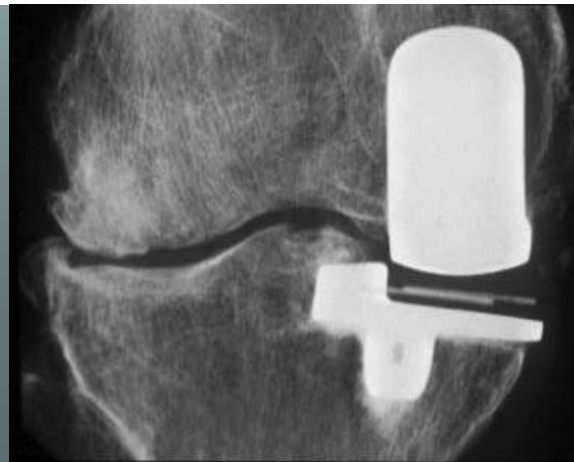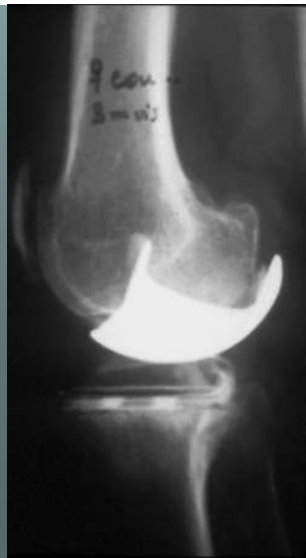Contraindications

Inflammatory diseases (chondrocalcinosis)

Bi or Tri-compartmental Osteoarthritis

Ligament Deficiencies

- ACL deficiency
- “True” Medial Collateral Ligament insufficiency



Expected result

UKA

1. No pain(95%), Forgotten knee(70%), Stability (98%), Walking distance (10km), Normal stairs, no limping no crutch, no swelling.
2. ... trekking, skating, Tennis
3. Complete extension, flexion 145° (preop ROM)
4. “*meniscus of the elderly*” (health status), immediate weight bearing, Hospitalisation (2 to 3 days), home or rehabilitation center (2 weeks), autonomy and driving (30days).
5. Monitoring++, Revision with TKA

Survival rate : **90% at 10 ys**

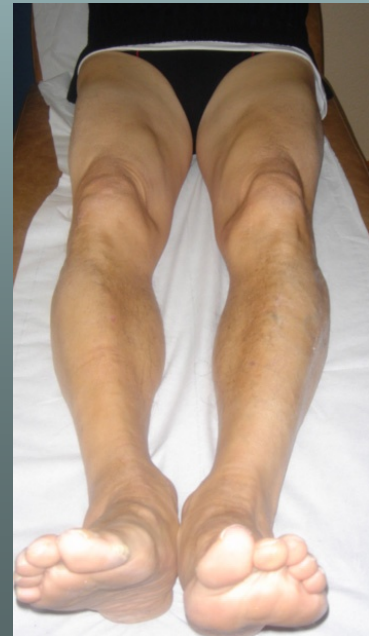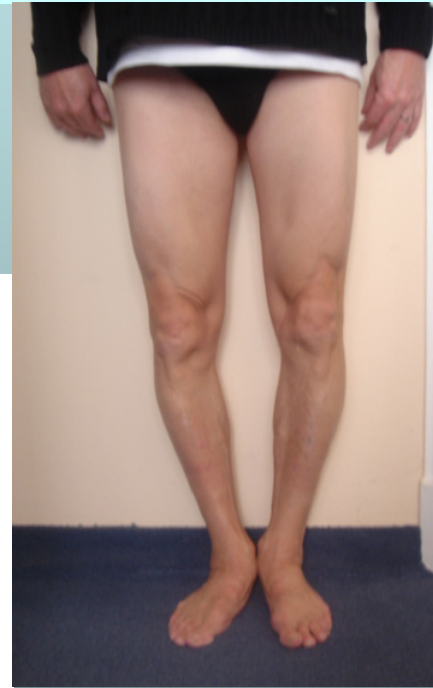
Infection : **0.5% at 10 ys post-op.**

НТО

Ideal candidate : HTO

Clinical exam

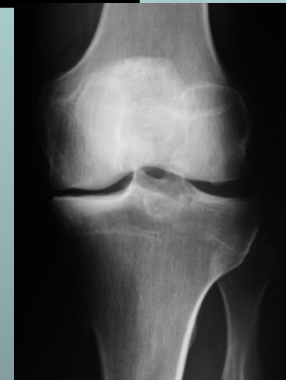
- Pain at the joint line
- ROM almost normal
- Ligament status OK
- No reducibility of deformity
- No inflammatory history
- Age < 65 y
- No obesity No smoker



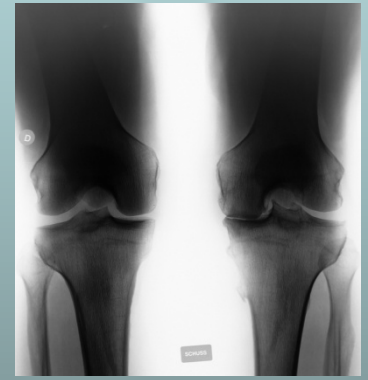
Ideal candidate: HTO

Radiological check-up

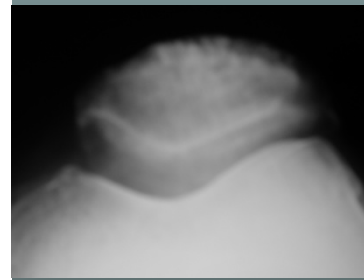
- **Partial** or complete femoro-tibial narrowing
- Normal contralateral and patello-femoral compartment



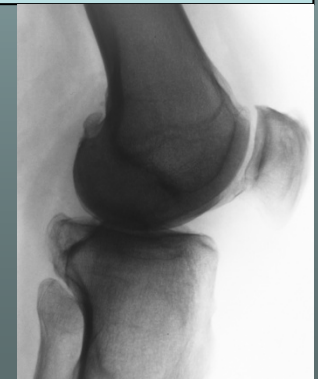A-P monopodal



Schuss



Axial view

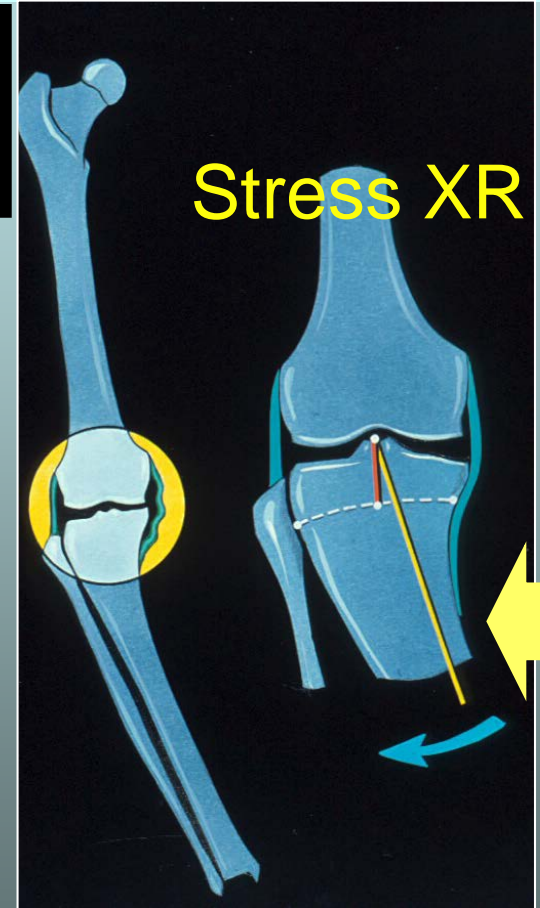


Profil

Ideal candidate: HTO

Radiological check-up

- No overcorrection
- Extra-articular deformity
>5°



Goniometry


2 different situations

1. Constitutional Varus Deformity

« Ideal situation »

« Corrective »
osteotomy

→ Normocorrection

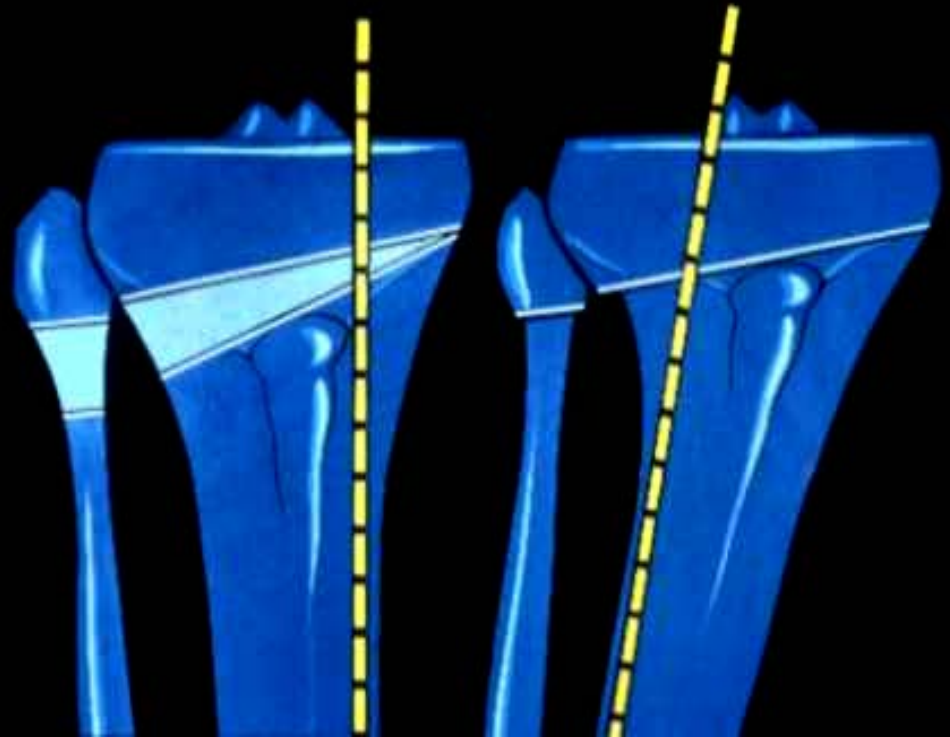


2 different situations

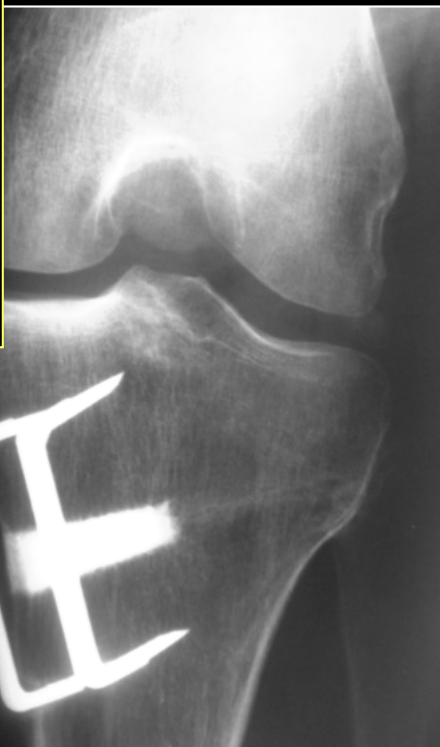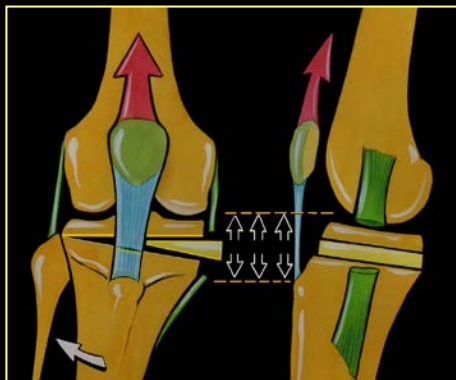
2. *No Constitutional Varus Deformity*

*« Palliative »
osteotomy*

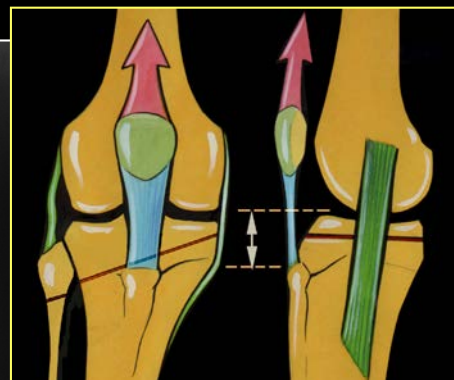
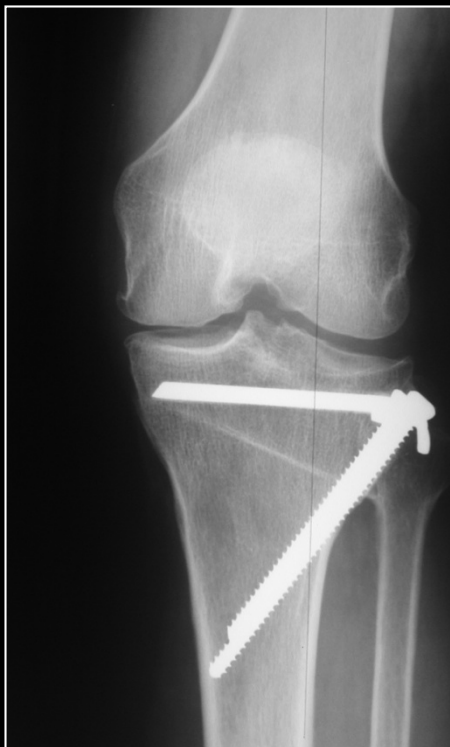
→ Overcorrection



Open vs Closed Wedge ?



Early O.A.
Younger patients



Established O.A.
Patella Infera
Older patient/ smoker

Limits ?

FPOA (asymptomatic) ?

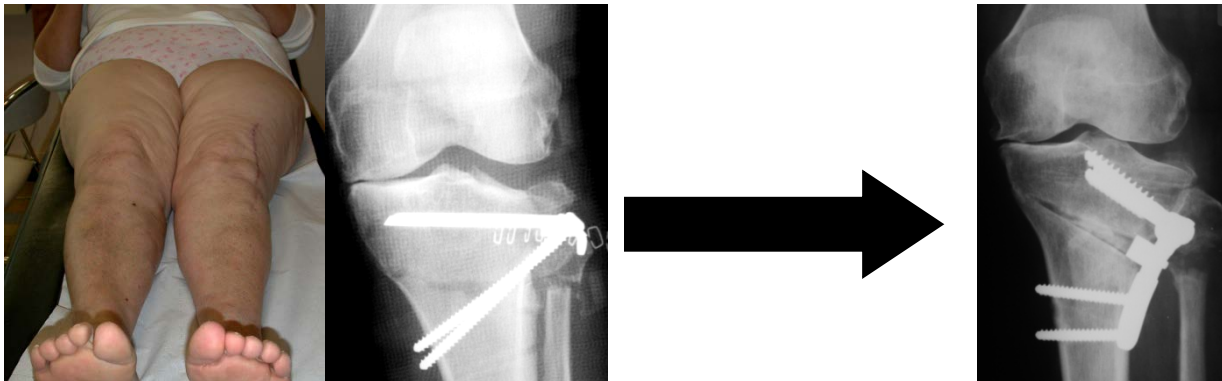
Flexion < 100° or fixed flexion contracture ?

Articular deformity, cupula ?

Age > 70 y ?

Smoker ?

Obese woman ???



Expected result

Osteotomy

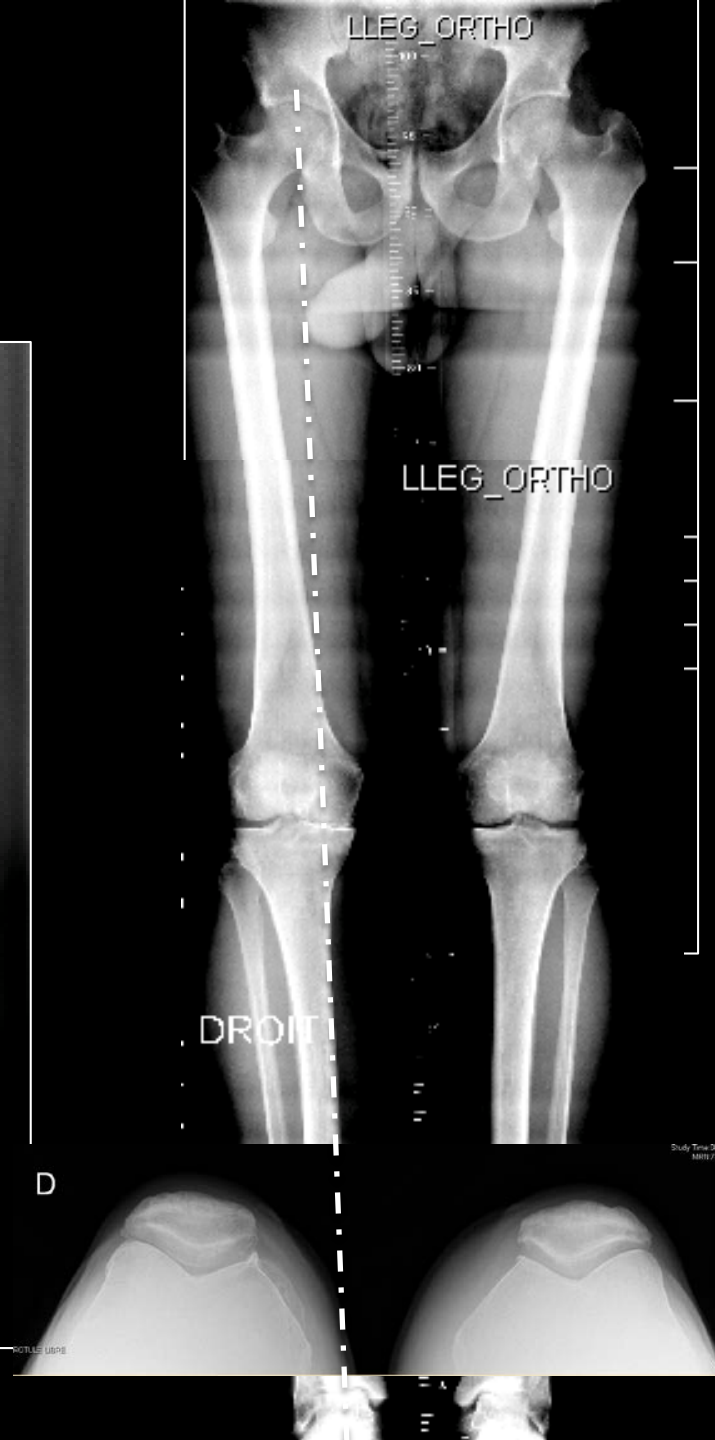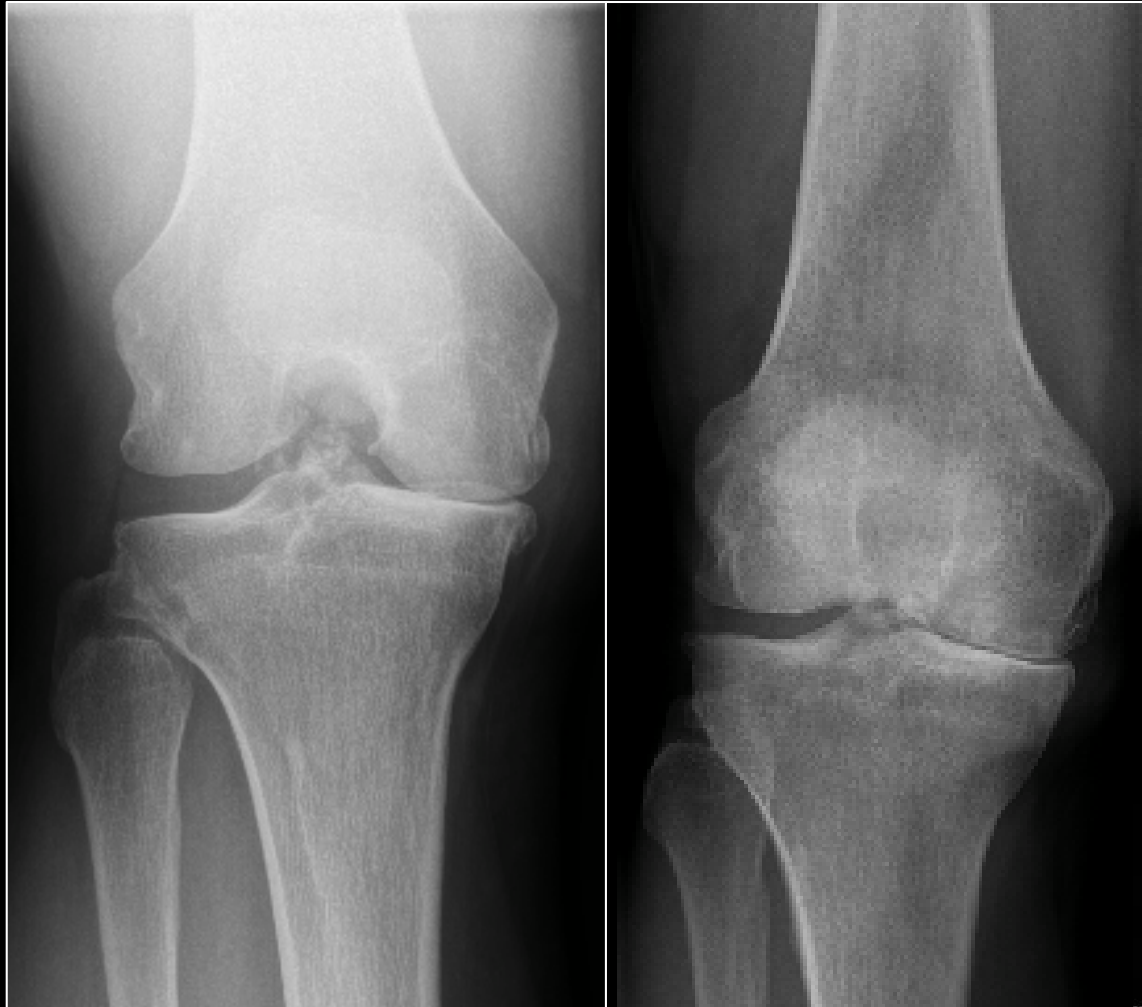1. No pain(95%), Forgotten knee(80%), Stability (90%), Walking distance (no limit), normal Stairs, no limping, no crutch, no swelling.
2. All sports
3. Complete extension, flexion 145° (preop ROM)
4. Restrictive intervention, Weight bearing delayed 2 months, (pre-op rehabilitation), Hospitalisation (1 to 2days), no rehab center, adaptation 4 to 6 months, autonomy and driving 45 days, valgus.
5. Revision with osteotomy or TKA.

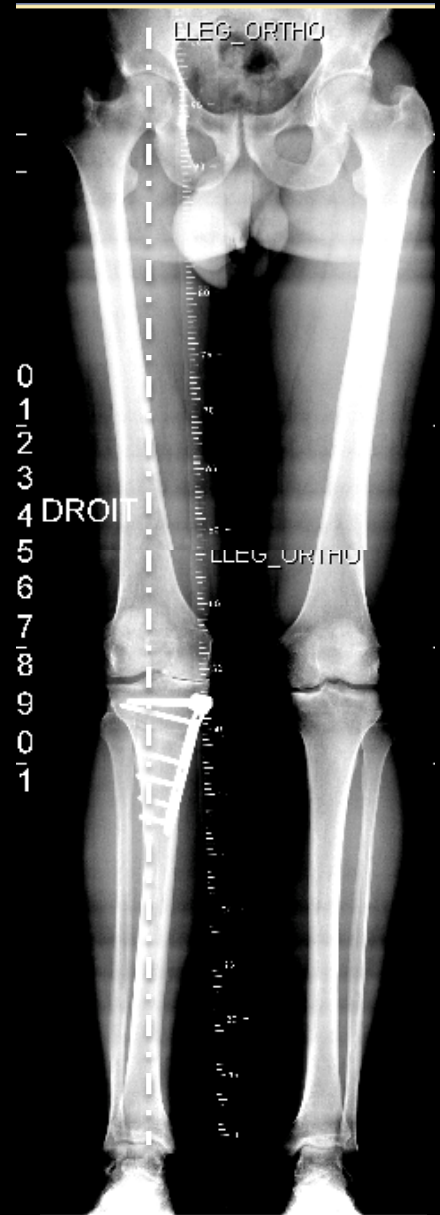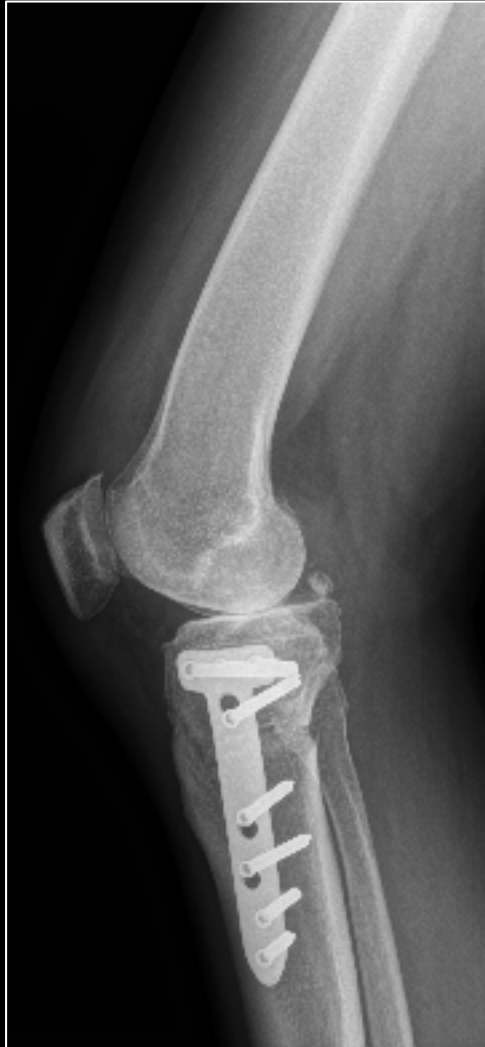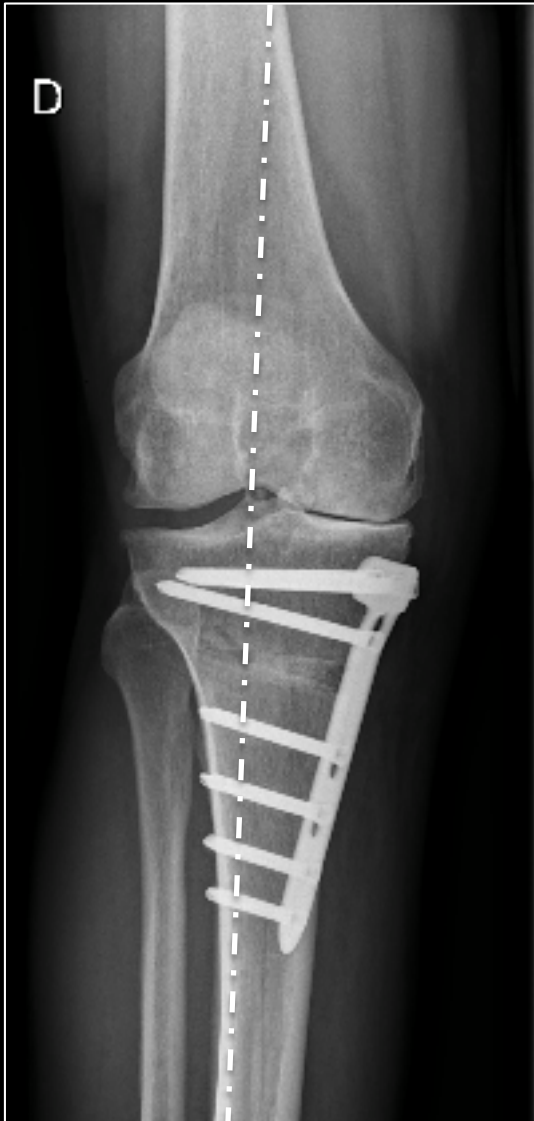Survival rate: 80% at 10 ys
Infection : < 0.5%

« borderline » Indications

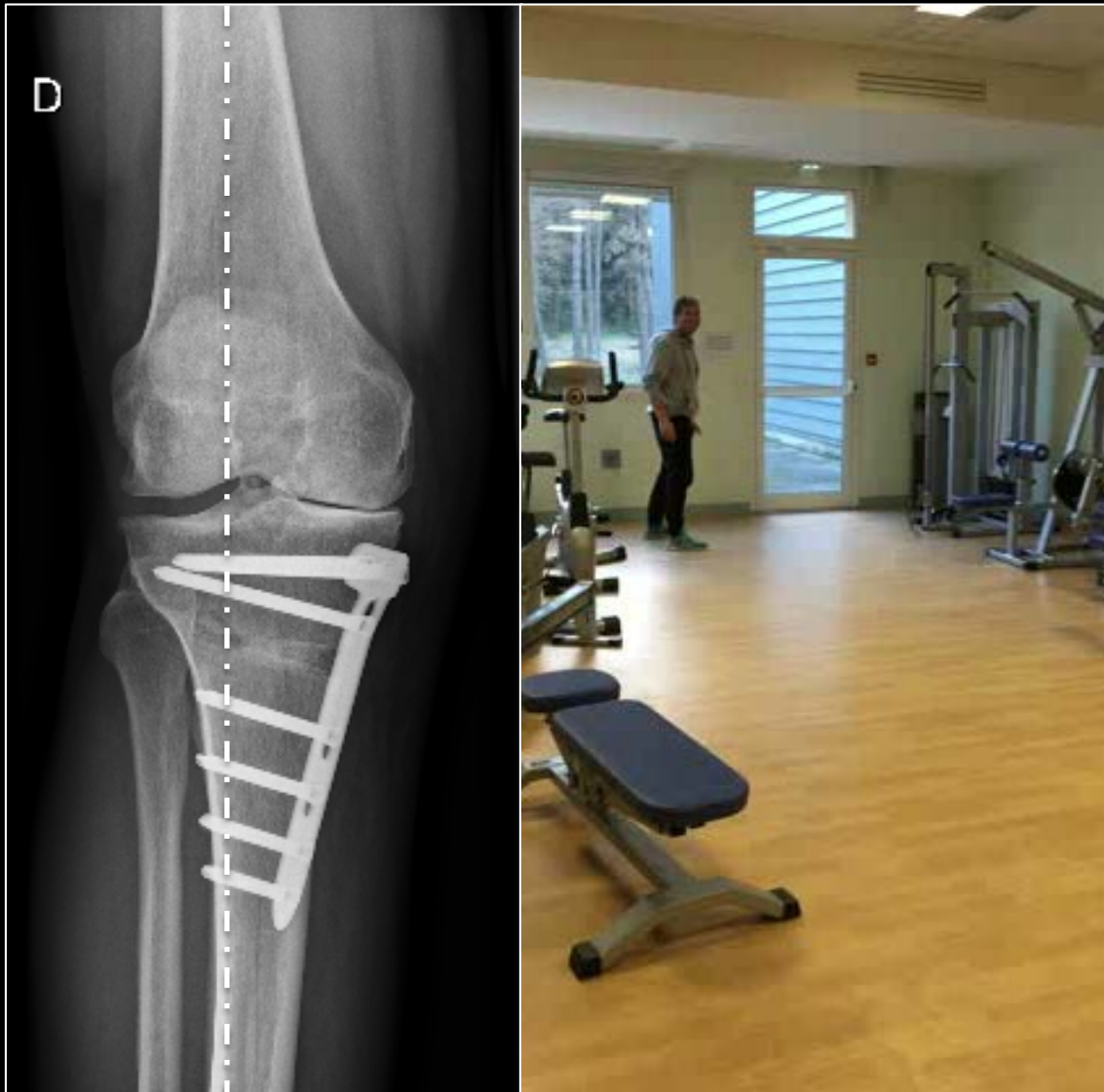- **Young patient** with **severe OA**, in order to delay the arthroplasty
- **Old patient** in good health but who really wants to keep on practicing highly demanding sport activities

60 years old Professional tennis player






3 months

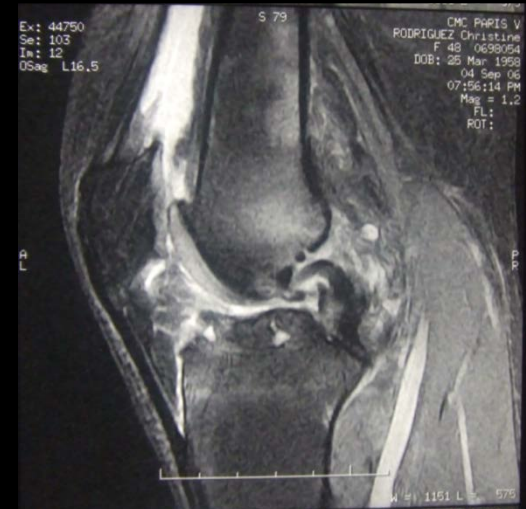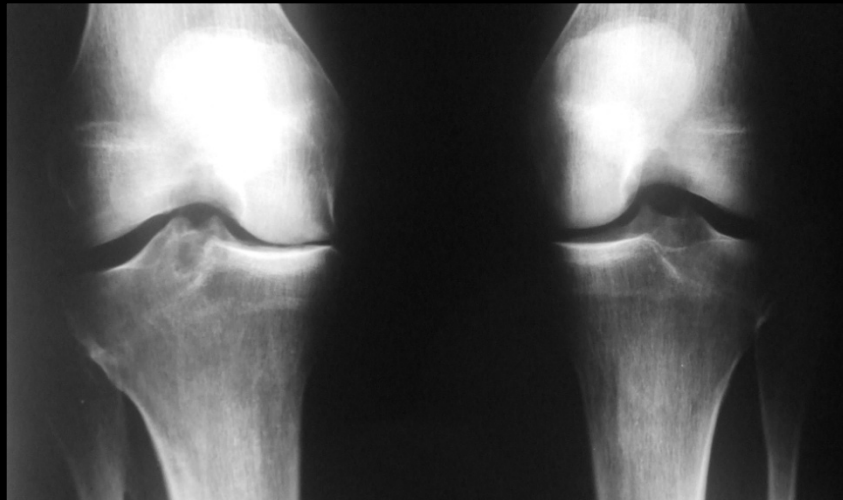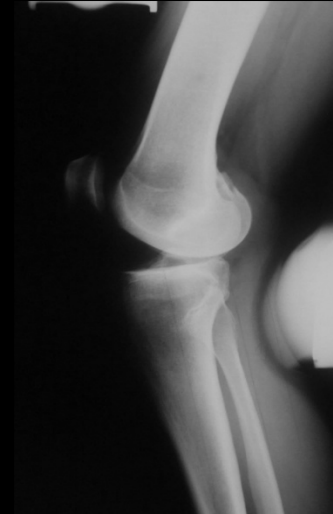


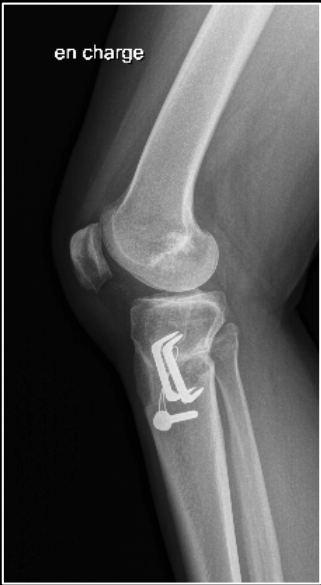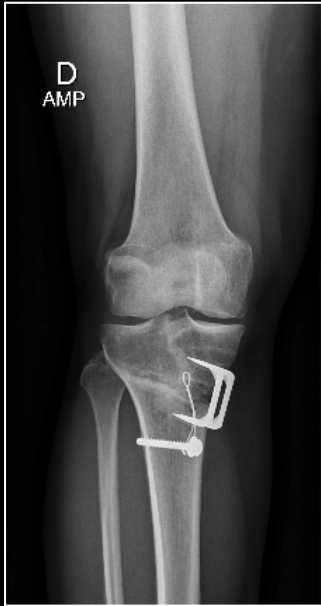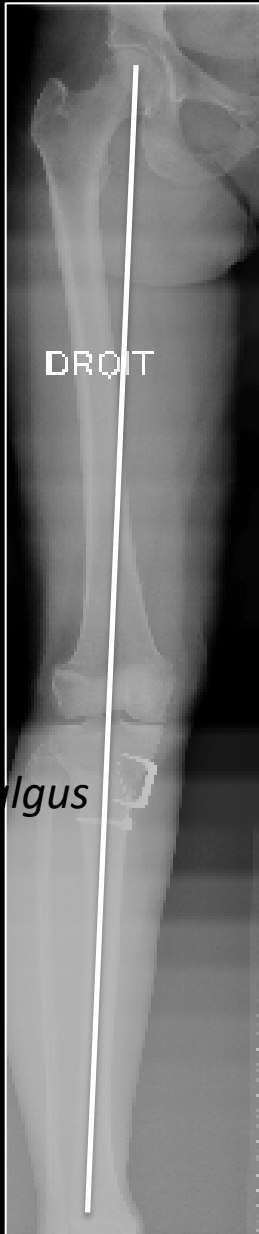1 year



MFTOA + ACL deficiency

Pre osteoarthritis +
anterior chronic laxity





Available online at
ScienceDirect
www.sciencedirect.com

Elsevier Masson France
EM|consulte
www.em-consulte.com/en



Original article

Anterior cruciate ligament reconstruction combined with valgus high tibial osteotomy allows return to sports

C. Trojani^{a,*}, H. Elhor^a, M. Carles^b, P. Boileau^a

^a Service de chirurgie orthopédique et traumatologie du sport, hôpital de l'Archet 2, 151, route de St-Antoine-de-Ginestière, 06200 Nice, France
^b Service d'anesthésie-réanimation, hôpital de l'Archet 2, 151, route de St-Antoine-de-Ginestière, 06200 Nice, France



No overcorrection...


53 ys old, 1 year post ACL + HTO



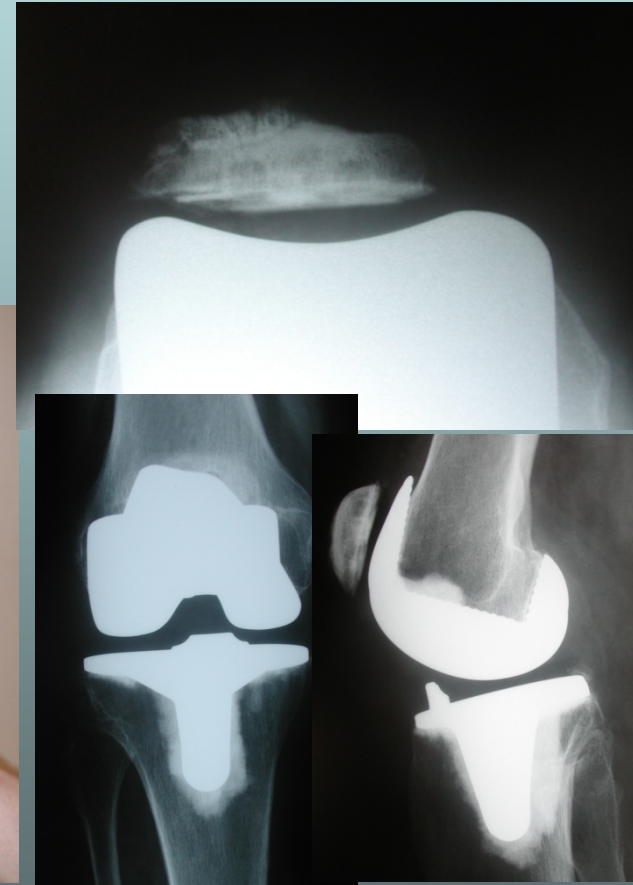
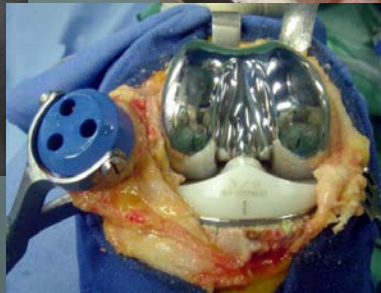
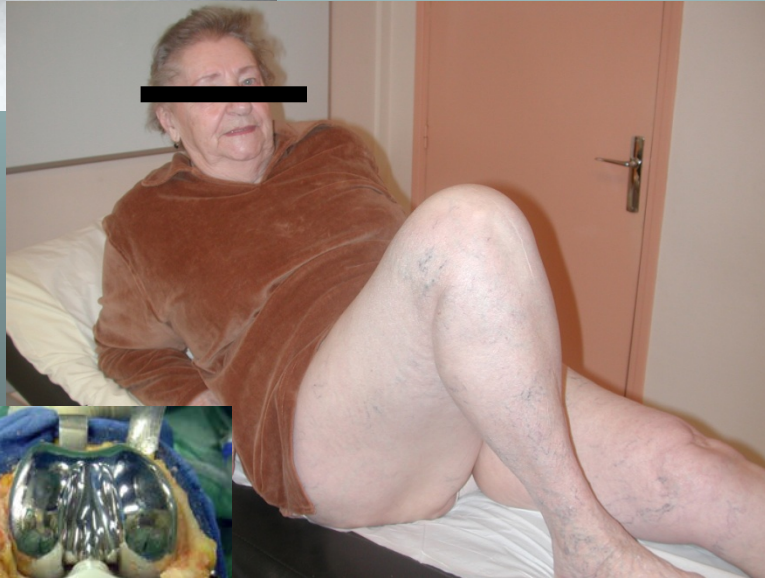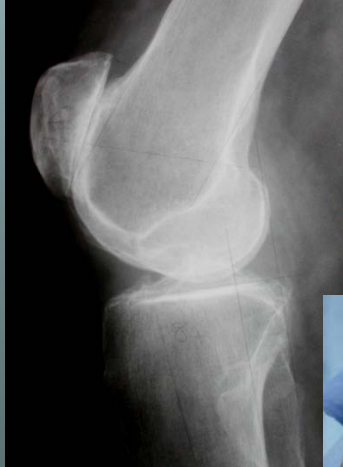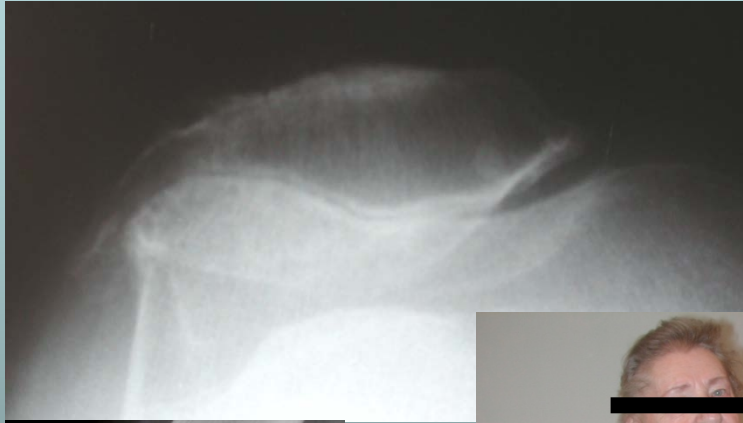TKA

But which one ?


Total knee arthroplasty



TKA

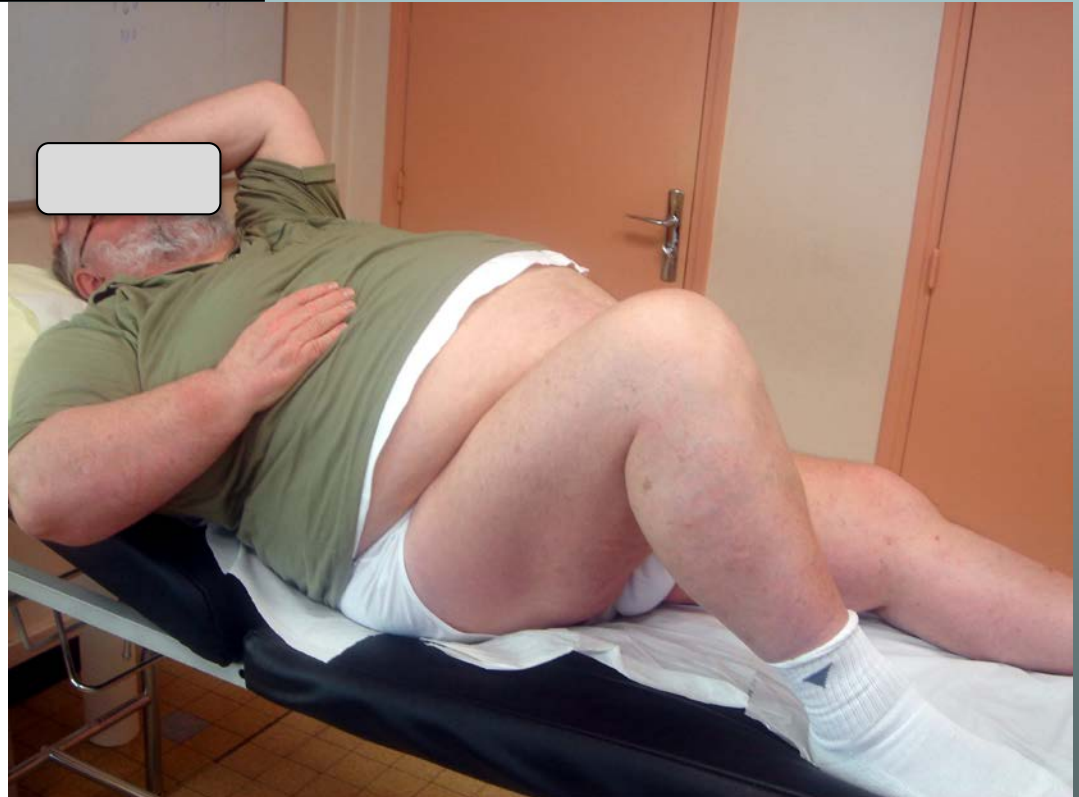

Total knee arthroplasty



Clinical consideration

- Disabling pain
- Other therapeutic options are not good indication
- Clinical relevance can influence decision (obesity...)



Expected result

TKA

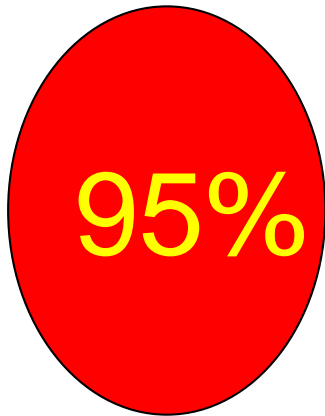
1. No pain(80%), Forgotten knee(40%), Stability (98%), walking distance (5km), Stairs , no limp, no crutch, swelling possible.
2. Hunting, golf, tennis (double), gardening.
3. Complete extension, flexion 120° (preop ROM)
4. Serious surgery (health of patient), immediate weight-bearing, hospitalisation (5-7 days), rehabilitation center (3-4 w), autonomy and driving (30-45 days)
5. Monitoring +, Revision with TKA

Survival rate : **90% at 15 y**

Infection : **1% for 10 y post-op.**

TKA

- Since 30 y
- Survival 20 y....
- Survival rate at 10 y



95%

- Abnormal function... avoid impacts...they rarely forget their knees... no important sport activity
- Sepsis 1.4%

Take Home Message


Anatomical criteria

- Stage of OA
- Analysis of the deformity and its reducibility
- Ligament status
- Range of motion

Clinical criteria

- Age and expectation
- Activity
- Weight
- General medical status (cardiovascular diabetes,plavix...)
- I Sepsis history

Osteotomy

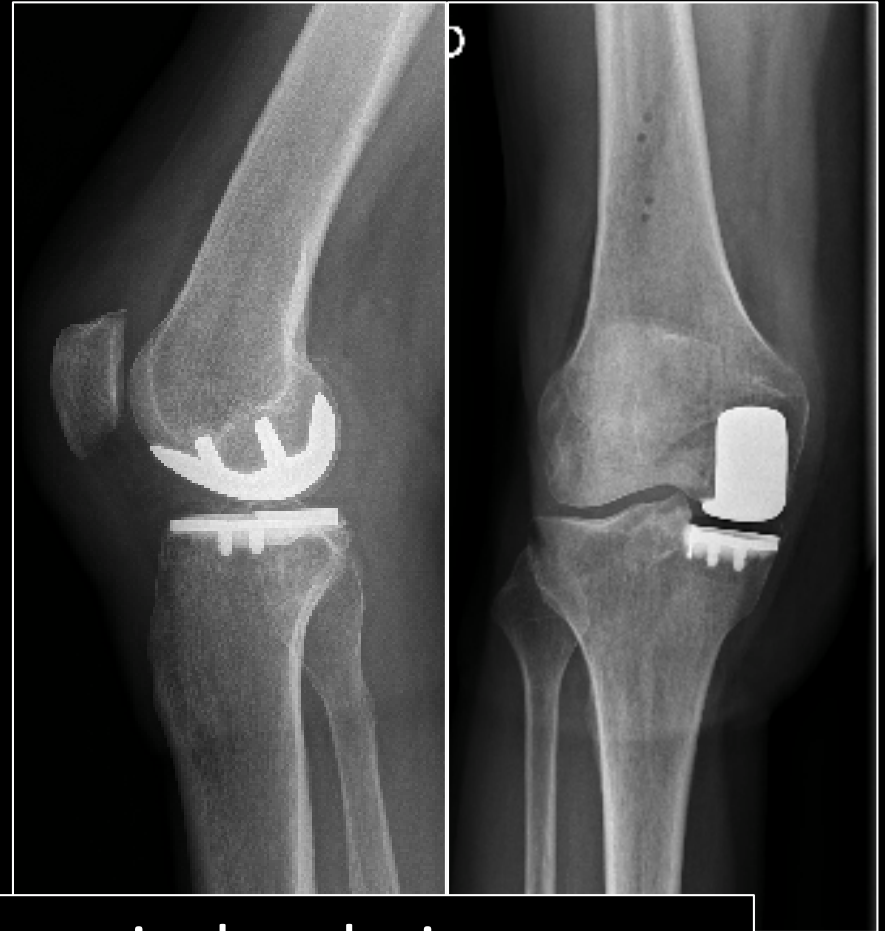


Total
Knee arthroplasty

Unicompartmental
knee arthroplasty

UKA

- Pain at the joint line,
- ROM almost normal,
- Bone on Bone OA,
- No constitutional varus deformity,
- Normal ligament testing,
- Reducibility of deformity,
- Over 65 years old,
- No obesity.



And an optimal surgical technique



Thank
You

Sebastien.lustig@gmail.com

7th Advanced Course on
Knee Surgery
January
14th - 18th 2018
Val d'Isère - France
www.kneecourse.com

Advanced course : Revision Knee Arthroplasty
18 èmes
Journées Lyonnaises
de Chirurgie du Genou
20 - 22
SEPTEMBER
2018
CENTRE CONGRÈS DE LYON
REGISTRATION : MCO CONGRÈS
CONTACT :
Email :
Phone :
INTERACTIVE SESSIONS
LYON KNEE SCHOOL of SURGERY
European Knee Society
EKS
LYON KNEE SCHOOL of SURGERY